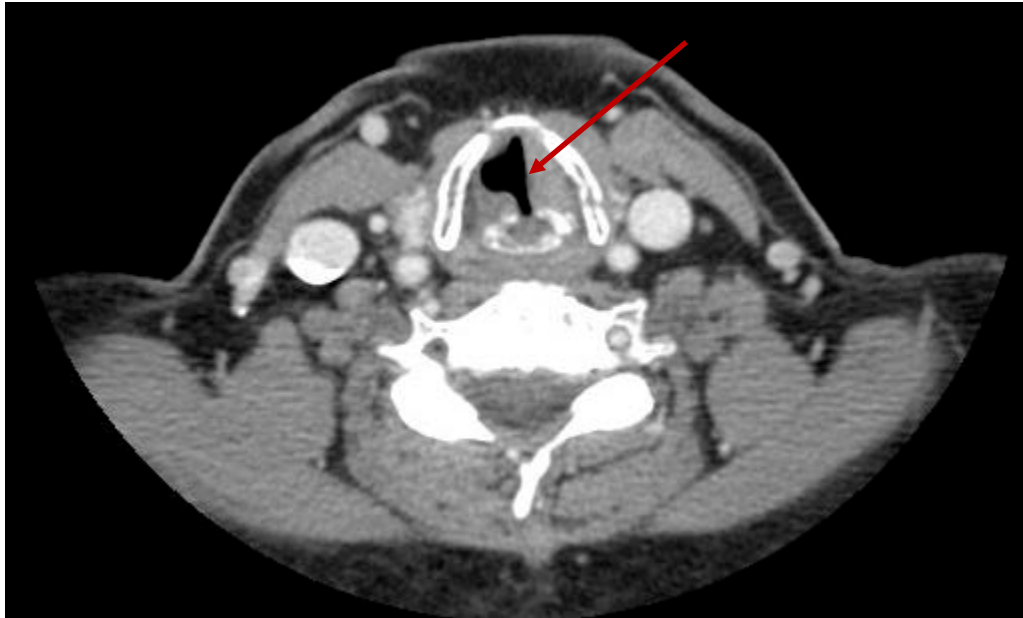


The right vocal cord is paralyzed in this patient with hoarseness, compare to the normal left vocal cord (red line).



The right recurrent laryngeal nerve is damaged by a right upper lobe lung cancer (red outline).

