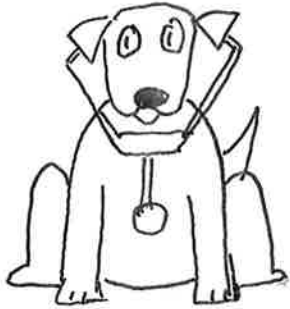
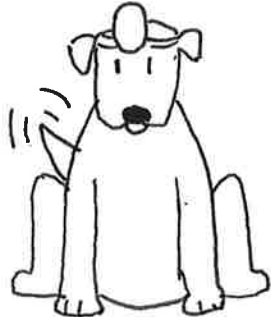
DRS. WOOF AND WAG TAKE A BITE
OUT OF CARPAL BONES!



DOGTOR WOOF



DOGTOR WAG

TODAY WE'RE GOING TO EAT TALK
ABOUT THE CARPAL BONES!

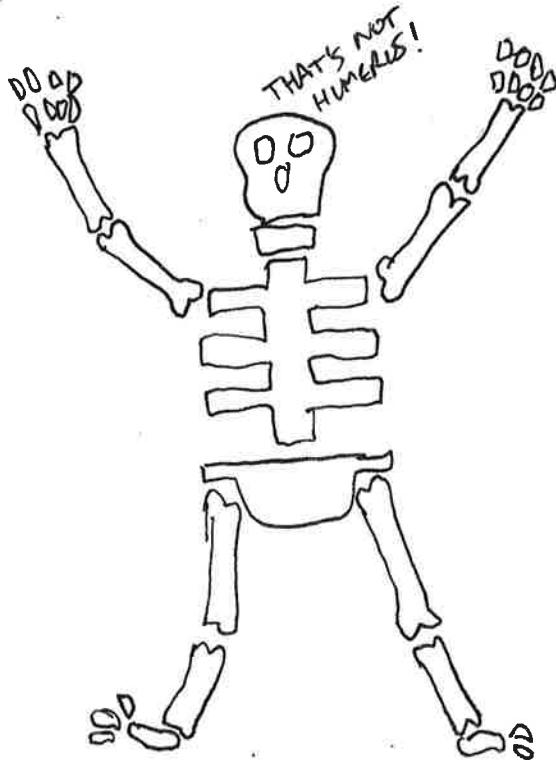
AS YOU CAN TELL
DOGTOR WAG IS
VERY EXCITED!



BY DANIEL SOK

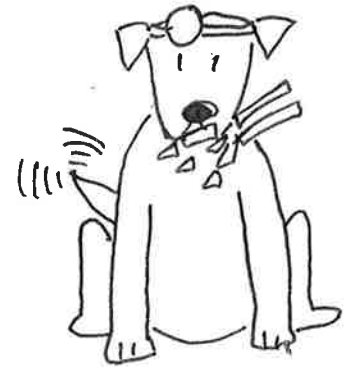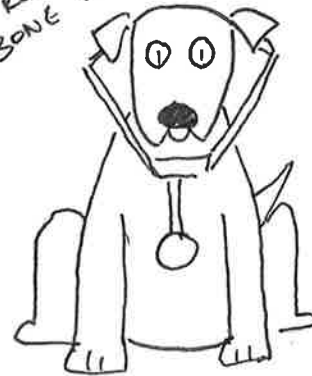SPECIAL THANKS TO: CAITLIN SOK

2

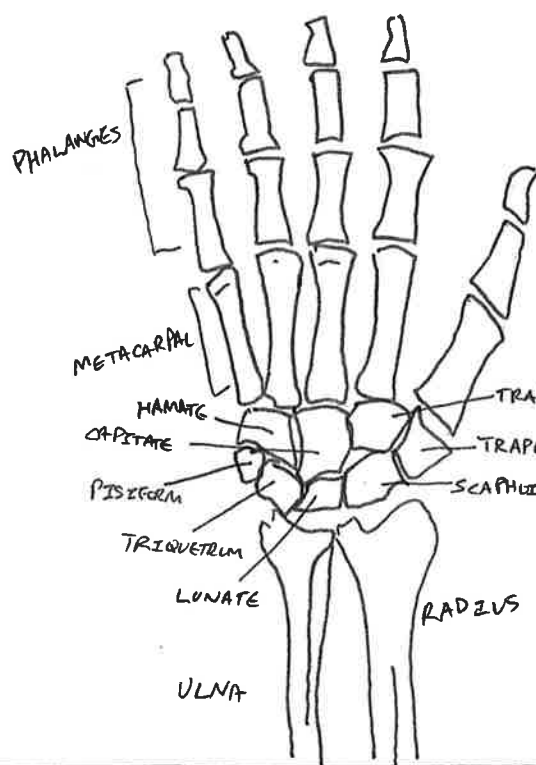


3

LOOKS LIKE DR. WAG
IS READY TO START.
BONE APPETIT!



4



CARPALS CONSIST OF 8 BONES

PROXIMAL: SCAPHOID
LUNATE
TRIQUETRUM
PISIFORM

DISTAL: HAMATE
CAPITATE
TRAPEZOID
TRAPEZIUM

MNEMONIC TO MEMORIZE THE BONES

Straight Line To Pinky

WE'LL START WITH THE SCAPHOID! (STRAIGHT)

Here Comes The Thumb



5

6

THIS BONE SEEMS TO BE THE LARGEST ON THE PROXIMAL ROW. IT ALSO TASTES LIKE SNIFF



IT'S THE MOST COMMON SITE FOR FRACTURES! IT'S ALSO PART OF THE ANATOMICAL SNIFF BOX



NEXT UP THE LUNATE! (LINE)

7

THIS ONE TASTES LIKE CHEESE



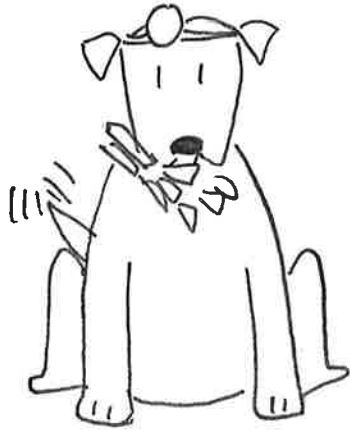THAT'S THE LUNATE BONE! IT'S GOT A DEEP CONCAVE AND CRESCENTIC OUTLINE



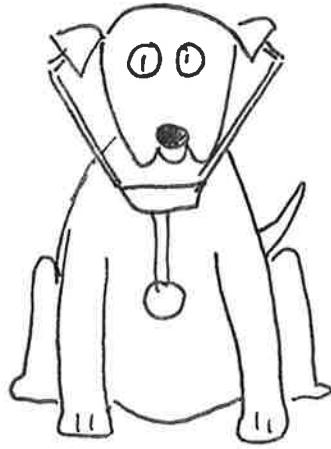NEXT UP THE TRIQUETRUM! (IO)

8

FEELS LIKE THIS
ONE HAS THREE
SIDES



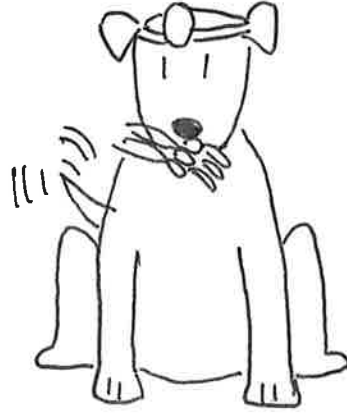THAT'S THE TRIQUETRUM
ALSO KNOWN AS THE
PYRAMIDAL BONE



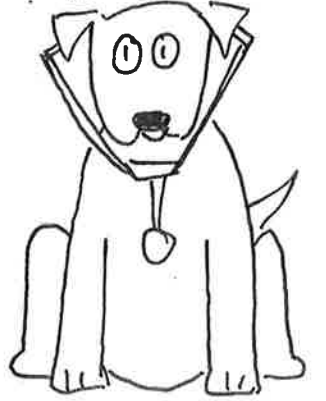NEXT UP THE
PISIFORM!
(PENNY)

9

THIS ONE FEELS
LIKE I'M EATING
A PEA



THAT'S THE PISIFORM!
IT FORMS THE ULNAR
BORDER OF THE CARPAL
TUNNEL. THE PISIFORM
IS THE ONLY CARPAL BONE
THAT DOES NOT TAKE PART
IN MOVEMENT.



NEXT UP THE
HAMATE!
(HERE)

10

THIS BONE REMINDS
ME OF THE TIME
I GOT HOOKED BY
THAT FISHING LINE



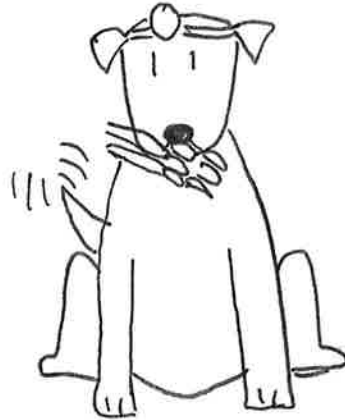THAT'S THE HAMATE
BONE. IT'S GOT A
HOOK LIKE PROCESS



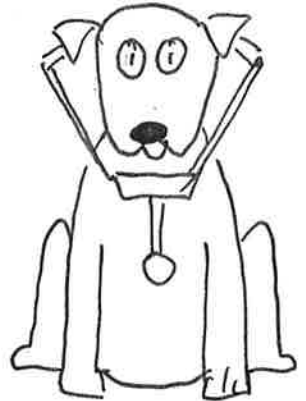
NEXT UP
THE CAPITATE!
(SONGS)

11

THIS IS
ONE LARGE
BONE!



THAT'S THE
CAPITATE BONE
THE LARGEST CARPAL
BONE.



NEXT UP
THE TRAPEZOID!
(I HE)

12

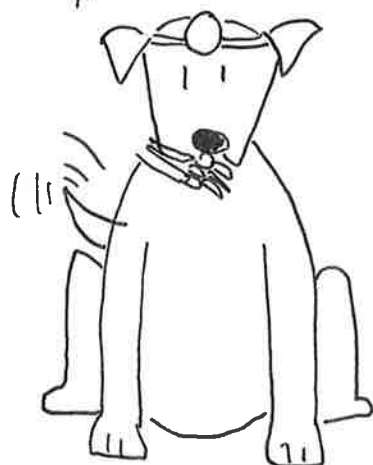THIS BONE
SEEMS LIKE
THE SMALLEST
ONE ON THE DISTAL
ROW



THAT'S THE
TRAPEZOID. THAT'S
ONE OF THE RAREST
BONES TO FRACTURE



IS THIS THE LAST
CARPAL BONE
MOST ADJACENT
TO THE THUMB?

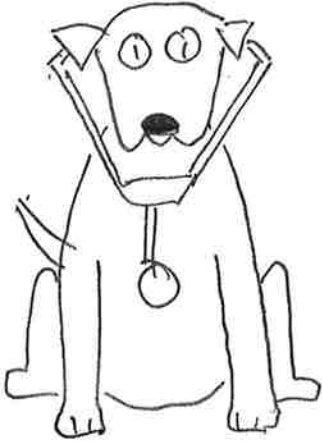


THAT'S THE
TRAPEZIUM!
IT'S MOST SUSCEPTIBLE
TO ARTHRITIS DUE TO
OVERUSE.

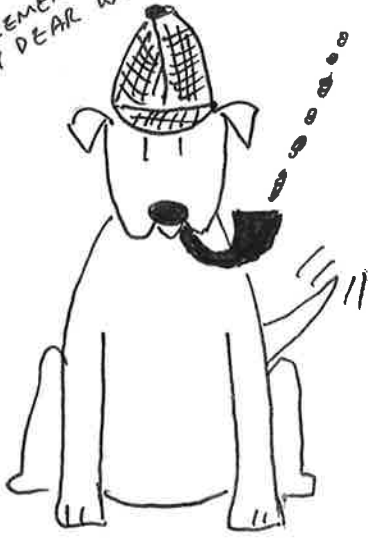

NEXT UP THE
TRAPEZIUM!
(THUMB)

YOU'RE A MODERN
DAY SHERLOCK
BONES DR. WAG



ELEMENTARY
MY DEAR WOODSON



THE END